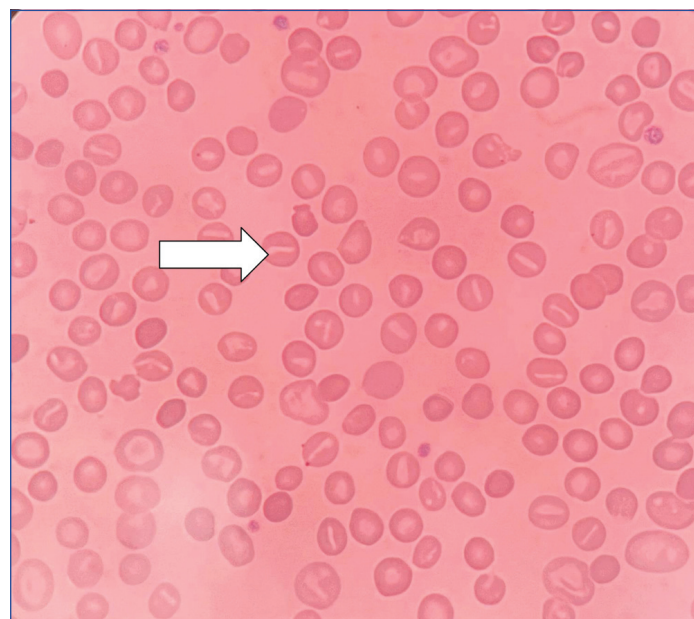


Hereditary Dehydrated Stomatocytosis due to PIEZO1 Mutation and Potential Therapeutic Target for Sickle Cell Anaemia

AFAQ AHMAD KHAN¹, SANTOSH G RATHOD²**Keywords:** Anaemia, Haemolytic anaemia, Hyperkalaemia

Dear Editor,

A 32-year-old female born out of a third-degree consanguineous marriage presented to the haematology clinic with generalised weakness, pallor, icterus, and pain in the left hypochondriac region. All these symptoms were for six months and progressive in nature. There was no history of similar complaints in other family members. On evaluation, the blood count showed: haemoglobin 9.9 g/L, red blood cell counts $3.37.000/\text{mm}^3$, white blood count of $7.1 \times 10^9/\text{L}$, platelets $128 \times 10^9/\text{L}$, Mean Corpuscular Volume (MCV) 98.3 fL, Mean Content Haemoglobin (MCH) 29.12 pg, Mean Corpuscular Haemoglobin Concentration (MCHC) 29.80 g/dL. Further evaluation revealed a total bilirubin of 2.4 mg/dL, indirect bilirubin of 2.1 mg/dL, Lactate Dehydrogenase (LDH) 1450 U/L, and haptoglobin of <8 mg/dL. The reticulocyte index on presentation was 9.0%, the electrolytes Na^+ was 135 Meq/L, and the K^+ was 4.5 Meq/L. The ultrasound of the abdomen showed splenomegaly 6 cm below the left costal margin. To find out the cause of haemolysis, we performed peripheral smear examination that showed numerous stomatocytes anisopoikilocytosis, macrocytes, microcytes and spherocytes [Table/Fig-1]. In order to rule out autoimmune haemolytic anaemia, Antinuclear Antigen (ANA), Anti-ds Deoxyribonucleic Acid (anti-ds DNA), and direct and indirect Coombs tests were performed, and they were all negative. The paroxysmal nocturnal haemoglobinuria profile was found to be negative. We performed High-Profile Liquid Chromatography (HPLC), showing HbA2 at 5.3%, HbA at 73%, and HbF at 0.5%, ruling out haemoglobinopathy as the cause of haemolysis. Genetic tests encoding the beta and alpha globin chains

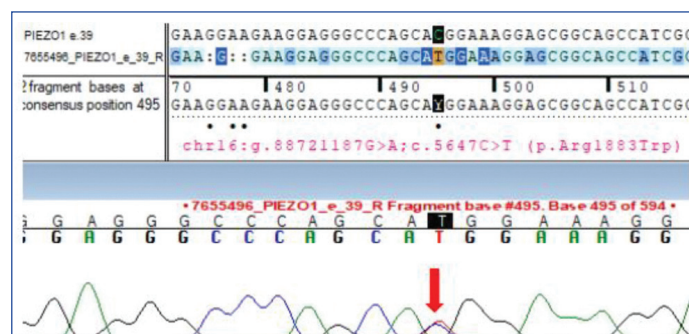


[Table/Fig-1]: In addition to anisopoikilocytosis, red blood cells from peripheral blood smear analysis also included stomatocytes (arrow), microcytes, macrocytes, and spherocytes.

ruled out structural modifications to haemoglobin. Enzyme activity related to red blood cell metabolism was normal. In order to rule out red blood cell structural defect as the cause of haemolysis, we performed the Eosin-5-Maleimide (EMA) test, which had a value within the normal range of 14% (normal test range $>11\%$), ruling out the spherocytosis. This test is normal in all forms of stomatocytosis. Osmotic fragility test was negative in this patient.

We could not do PINK test because of non-availability at our set-up. All these tests were performed to look for the defect in the red cell membrane [1,2].

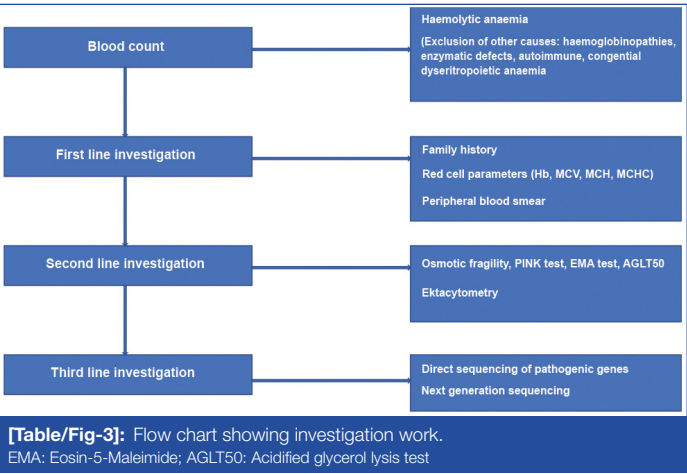
We performed additional tests, the glycerol lysis test and sodium dodecyl Sulfate-Polyacrylamide Gel Electrophoresis (SDS-PAGE), for quantification of red blood cell membrane protein that came negative and ruled out hereditary spherocytosis, elliptocytosis and pyro poikilocytosis. In view of dehydrated stomatocytosis, ektacytometry was performed that measured the erythrocyte deformability by subjecting them to osmotic stress, showing a left shift of osmolarity curve, and giving a clue to the Dehydrated Hereditary Stomatocytosis (DHS). The genetic test was performed and results of a targeted-NGS custom panel made up of hereditary anaemias were positive for the PIEZO1 gene's exon 39 containing a heterozygous missense variant on chromosome 16 (c.5647C>T) that causes Tryptophan to be substituted for Arginine at codon 1883 (p. Arg1883Trp) [3]. The Sanger sequence provided evidence for this gene [Table/Fig-2]. The variation was identified as pathogenic insilico analysis. The current mutation was completely novel in an Indian population.



[Table/Fig-2]: Sequence chromatogram and alignment to the reference sequence showing the variant in exon 39 of the PIEZO1 gene (chr16:g.88721187G>A; c.5647C>T; p.Arg1883Trp) detected in the heterozygous condition.

DHS is brought on by a change in the RBC membrane's permeability to the monovalent cations Na^+ and K^+ due to a mutation in the PIEZO1 gene that codes for a mechanoreceptor [3]. This affects the intracellular cationic content and results in cell dehydration and volume changes. Invertebrates and vertebrates alike use mechanoreceptors, which are cation channels that are activated by many kinds of mechanical stimuli, as biological pressure sensors [1,3]. The primary causal gene for this condition is PIEZO1, which is located at 16q23–24 and inherited in an autosomal dominant pattern [2,3]. At the RBCs' plasma membrane, it is highly expressed [3].

There is a chance of misdiagnosis since DHS and hereditary spherocytosis share several characteristics, and a sequential diagnostic algorithm is required to diagnose the condition [Table/ Fig-3]. In DHS, haemolysis occurs intravascularly. Hence, splenectomy does not have a role in such patients [1]. If splenectomy is done in such a patient, they are prone to thrombosis of the portal vein and pulmonary hypertension. Female patients can develop pseudohyperkalaemia during pregnancy [1,3].



The aim of treatment is to reduce complications from chronic haemolysis and anaemia. If a newborn is suspected of having hereditary dehydrated stomatocytosis, in that case, one should not wait for diagnostic confirmation; start treating hyperbilirubinaemia and, in severe cases, blood transfusion or exchange transfusion should be performed [1,2]. The transfusion of red blood cells may be required for severely affected infants and in aplastic crisis. There is an increased requirement for folate due to stress erythrocytosis. The dose for children with moderate to severe haemolysis is 1 to 2 mg/day [9,10]. Transfusions are required at any time of life in adult

patients due to aplastic and haemolytic crises, and iron metabolism should be regularly checked for the risk of developing severe hepatic iron overload [1,2].

PIEZO1 channels have a significant role in sickle cell crisis related to sickle cell anaemia. When HbS (sickle) is deoxygenated in the venous system, it allows sickle cells to become permeable to calcium through PIEZO1 channels, which initiates a dehydration cascade influenced by the outward electrochemical gradient of potassium [4]. The deoxygenation of HbS causes PIEZO1 channels to activate, facilitating Ca²⁺ entry following its steep inward electrochemical gradient. Increased intracellular calcium concentration {(Ca²⁺)_i} activates the calcium-sensitive Gardos channels (KCNN4), resulting in a net loss of KCl and water [4]. The irreversibly sickled cells exist in this hyperdense yet volume-stable and pathogenic condition for most of their life cycle in circulation until a decline in sodium pump activity causes sudden rehydration and subsequent cell lysis [4].

The patient received guidance about the contraindications of splenectomy, the risks of iron overload, and the necessary follow-up during pregnancy. Currently, she is taking 5 mg of folic acid daily in tablet form. She has been effectively treated for haemolytic anaemia.

Acknowledgement

Special thanks to Dr. Vidya Wadate for her constant support.

REFERENCES

[1] Zama D, Giulietti G, Muratore E, Andolfo I, Russo R, Iolascon A, et al. A novel PIEZO1 mutation in a patient with dehydrated hereditary stomatocytosis: A case report and a brief review of literature. Ital J Pediatr. 2020;46:102.

[2] Sharma R, Jain A. Red cell membranopathies: Case series and review of literature. Pediatr Hematol Oncol J. 2024;9:65-73.

[3] Ge J, Li W, Zhao Q, Li N, Chen M, Zhi P, et al. Architecture of the mammalian mechanosensitive Piezo1 channel. Nature. 2015;527:64-69.

[4] Lew VL, Rogers SD. Hyperactive deoxy-PIEZO1 shapes the circulatory life cycle of irreversibly sickled cells. Biophys J. 2025;124:1183-94.

PARTICULARS OF CONTRIBUTORS:

- 1. Assistant Professor, Department of Clinical Haematology, SKIMS, Srinagar, Jammu and Kashmir, India.
- 2. Assistant Professor, Department of Clinical Haematology, AIIMS, Nagpur, Maharashtra, India.

NAME, ADDRESS, E-MAIL ID OF THE CORRESPONDING AUTHOR:

Santosh G Rathod,
Type-5, AIIMS, Nagpur-441108, Maharashtra, India.
E-mail: drsgrathod2007@gmail.com

AUTHOR DECLARATION:

- Financial or Other Competing Interests: None
- Was Ethics Committee Approval obtained for this study? Yes
- Was informed consent obtained from the subjects involved in the study? Yes
- For any images presented appropriate consent has been obtained from the subjects. Yes

PLAGIARISM CHECKING METHODS: [Jain H et al.]

- Plagiarism X-checker: Jan 28, 2023
- Manual Googling: May 02, 2025
- iThenticate Software: May 15, 2025 (9%)

ETYMOLOGY: Author Origin

EMENDATIONS: 6

Date of Submission: Jan 20, 2023
Date of Peer Review: Mar 20, 2023
Date of Acceptance: May 17, 2025
Date of Publishing: Jul 01, 2025